

## ANALYSIS OF SUBCOCHLEAR CANALICULUS PATTERNS IN THE ADULT POPULATION ON HRCT TEMPORAL BONE: OUR EXPERIENCE

Faulad Md Noori<sup>1</sup>, Sanjay Kumar Mandal<sup>2</sup>, Md Akbar Ali<sup>3</sup>, A.K. Singh<sup>4</sup>, Suman Maurya<sup>5</sup>, Maroof Shahedi<sup>6</sup>, Syed Murthuza<sup>7</sup>

Received : 04/03/2024  
Received in revised form : 25/04/2024  
Accepted : 11/05/2024

**Keywords:**

HRCT temporal bone, Funiculus, Fustis, Petrous apex pneumatization, Subcochlear canaliculus.

Corresponding Author:

**Dr. Suman Maurya,**

Email: mynotepad13556@gmail.com

DOI: 10.47009/jamp.2024.6.2.190

Source of Support: Nil,

Conflict of Interest: None declared

*Int J Acad Med Pharm*  
2024; 6 (2); 925-928



<sup>1</sup>Associate Professor, Department of ENT, KMCH, Katihar, Bihar, India

<sup>2</sup>Assistant Professor, Department of ENT, KMCH, Katihar, Bihar, India

<sup>3</sup>Professor, Department of ENT, KMCH, Katihar, Bihar, India

<sup>4</sup>Professor, and Head, Department of ENT, KMCH, Katihar, Bihar, India

<sup>5</sup>2<sup>nd</sup> Year JR, Department of ENT, KMCH, Katihar, Bihar, India

<sup>6</sup>3<sup>rd</sup> Year JR, Department of ENT, KMCH, Katihar, Bihar, India

<sup>7</sup>1<sup>st</sup> Year JR, Department of ENT, KMCH, Katihar, Bihar, India

### Abstract

**Background:** Subcochlear canaliculus is an anatomical space between fustis, funiculus and anterior pillar of round window. It has variable extension under cochlea to petrous apex. It is of three types according to the extension below the cochlea. **Materials and Methods:** This retrospective observational study carried out in katihar medical college, Katihar during the period of 1<sup>st</sup> June 2022 to 31<sup>st</sup> January 2024. 50 patients above 18years of age who had undergone temporal bone CT scan for diagnostic purpose were randomly included. **Result:** In age group 15 to 30 years, type B pattern was more (70%) in comparison to other types, in age group 31 to 45years and 46 to 60 years type A and type B patterns were almost equal. But in more than 60 years of age type a pattern was more (69%) common in comparison to other types. **Conclusion:** Knowledge of temporal bone pneumatization patterns and anatomy of medial wall of round window is very important during preoperative planning for otoneurological surgery particularly petrous apex cholesteatoma.

## INTRODUCTION

Pneumatized temporal bone acts as air reservoir and a pressure regulator for middle ear to prevent tympanic membrane retraction.<sup>[1]</sup> Pneumatization pattern of temporal bone is different for different individuals.<sup>[2]</sup> It is influenced by genetic and environmental factors like middle ear infection, cholesteatoma, fracture etc.<sup>[3]</sup> Mastoid antrum is the first part of temporal bone to get pneumatized and present at birth but Petrous apex pneumatization is the last step of the development.<sup>[4]</sup> It is very difficult to locate and measure the size of temporal bone pneumatization due to its compactness. Previously, temporal bone pneumatization pattern being evaluated indirectly and quantitatively by methods like water-weight, pressurized transducer, and acoustic methods but nowadays radiological methods like lateral radiography and computed tomography are being used, which requires less time and effort on the part of the subject.<sup>[5]</sup> The round window chamber is a three dimensional area between round window niche and round window membrane.<sup>[6]</sup> The round window niche is an anatomical bony structure which forms the entrance of cochlear membrane; it gets

merge postero-laterally to the inferior retro tympanum and it lies between the funiculus antero-infero-laterally and subiculum postero-superolaterally.<sup>[7]</sup> The round window niche is triangular in shape bounded by anterior pillar, tegmen, and the posterior pillar.<sup>[7]</sup> Funiculus is a bony structure that arises from the anterior pillar, and runs downward towards the hypotympanum where the jugular bulb is located and separates the inferior retrotympanum from the hypotympanum.<sup>[7]</sup> Fustis is a thick smooth bone within the round window chamber, extends from the styloid complex into round window niche and pointing towards the round window membrane.<sup>[7]</sup> A tunnel between the funiculus and fustis is formed by pneumatization called as Proctor's area concamerata. It connects middle ear cavity to petrous bone cells and lies below the cochlea, hence also called as sub cochlear canaliculus.<sup>[7,8]</sup> So, Subcochlear canaliculus is an anatomical space between fustis, funiculus and anterior pillar of round window. It has variable extension under cochlea to petrous apex. It is of three types according to the extension below the cochlea. Type A [Figure 1a & 1b] is a deep tunnel with extension up to the petrous apex, here HRCT temporal bone coronal view shows the

presence of a well-pneumatized bone in the most inferior and medial portion of the petrous apex, below the internal auditory canal. Type B [Figure 2] is a small tunnel between the fustis and the funiculus, here coronal view of HRCT scan shows the presence of a limited pneumatized bone below the cochlea. In type C [Figure 3] there is no air cells present below cochlea because the fustis and Proctor's area concamerata get merged with funiculus and anterior pillar.<sup>[7]</sup> Knowledge of temporal bone pneumatization patterns and anatomy of medial wall of round window is very important during preoperative planning and otoneurological surgery particularly petrous apex cholesteatoma and cochlear implant surgery. In cochlear implant surgery, round window niche may be mistaken with subcochlear canaliculus and the array of electrodes are placed in infracochlear cells instead of in the scala tympani, which is very close to the internal carotid artery and might get damaged. This mistake happens because the subcochlear canaliculus tunnel is grossly similar in orientation to the scala tympani.<sup>[9]</sup> In case of cholesteatoma of the round window region, matrix may involve the subcochlear canaliculus and extend towards the petrous apex. So, an exploration of subcochlear canaliculus is mandatory during cholesteatoma surgery to avoid residual disease in hidden area, which may later develops into a residual cholesteatoma of the petrous apex. Subcochlear canaliculus corridor may be used in endoscopic infracochlear approach to internal auditory canal for resection and drug delivery in case of vestibular schwannoma without hampering hearing; vestibular dysfunction and cerebrospinal fluid leak.<sup>[10-13]</sup> The objective of this study is to analyze the patterns of the subcochlear canaliculus in adult population through HRCT temporal bone.

## MATERIALS AND METHODS

This retrospective observational study carried out in Katihar medical college, Katihar during the period of 1<sup>st</sup> June 2022 to 31<sup>st</sup> January 2024. 50 patients above 18 years of age who had undergone temporal bone CT scan for diagnostic purpose were randomly included.

### Inclusion criteria:

- Patient undergone HRCT temporal bone for tympanomastoid surgery.
- Adult patients more than 18 years of age.

### Exclusion criteria:

- Patients who had undergone previous otological surgery.
- Patients with middle or inner ear malformations.

CT acquisition parameters Scans were performed with a GE 16 slice CT machine. Acquisition parameters were: 140 kV; 150 mA; slice thickness 0.625 mm; matrix 512×512. The CT scans were reviewed by senior radiologist and otolaryngologist. The subcochlear canaliculus was examined through coronal section scan at the level of the round window niche. Subcochlear canaliculus patterns were

analyzed. The study was approved from institutional ethical committee of our institution.

### Statistical analysis:

Statistical analysis was performed using SPSS-20 version software. Univariate analysis of the data was conducted. The Chi-square test and Fisher exact test was used for normally distributed continuous variables. Statistical significance was set for p value of <0.05.

## RESULTS

This study was conducted in Katihar Medical College, Katihar during the period of 1<sup>st</sup> June 2022 to 31<sup>st</sup> January 2024. Total 50 patients who had undergone CT scan of temporal bone were included in study. So, total 100 temporal bones were analyzed. Three types of subcochlear canaliculus were analyzed in coronal section of temporal bone computed tomography scan. Patients were subdivided into four groups that are 15 to 30yrs, 31 to 45yrs, 46 to 60yrs and more than 60 years of age to analyze the patterns of subcochlear canaliculus. The results were analyzed according to age, laterality and different patterns in adult and elderly population. The data are summarized as below.

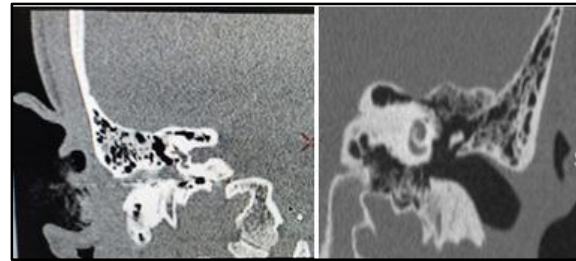


Figure 1a: Type A. Figure. 1b: Type A



Figure 2: Type B

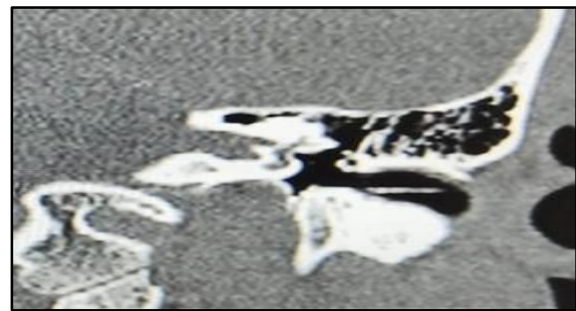


Figure 3: Type C

**Table 1: Age distribution**

Age (in yrs)	Total no. of patients	Male	Female
15-30	25	15	10
31-45	12	7	5
46-60	5	5	0
>60	8	3	5

**Table 2: Relation between age and subcochlear canaliculus patterns**

Age (in years)	Total no. of T. Bone examined	Type A	Type B	Type C
15- 30	50	14(28%)	35(70%)	1(2%)
31-45	24	11(46%)	12(50%)	1(4%)
46-60	10	5(50%)	5(50%)	0(0%)
>60	16	11(69%)	3(19%)	2(12%)

**Table 3: Comparison of Type a pattern in adult and elderly**

	Type A	Non -Type A	Total
Adult	30	54	84
Elderly	11	5	16

**Chi-square test= 4.77**

P value = .029(significant) that means Type A pattern is significantly higher in adult population than in elderly population.

**Table 4: Comparison of Type B pattern in adult and elderly**

	Type B	Non- Type B	Total
Adult	52	32	84
Elderly	3	13	16

**Chi -square test= 8.44**

P value= .0037(significant) that means type B pattern is also significantly higher in adult population than in elderly population.

**Table 5: Comparison of Type C pattern in adult and elderly**

	Type C	Non – Type C	Total
Adult	2	82	84
Elderly	2	14	16

**Chi- square =1.43**

P value=.23 (non-significant), there is no significant association of type C pattern in adult and elderly population.

## DISCUSSION

Out of 50 patients, there were 30 male and 20 female patients. The human being is classified into four categories according to age that are Child (0-12years), Adolescence (13-18 years), Adult (19-59years) and Senior Adult (60 years and above).<sup>[14]</sup> In age group 15 to 30 years, type B pattern was more (70%) in comparison to other types, in age group 31 to 45years and 46 to 60 years type A and type B patterns were almost equal. But in more than 60 years of age type a pattern was more (69%) common in comparison to other types. We have also compared subcochlear canaliculus patterns between adult and elderly.

In our study, on comparison of type A pattern in adult and elderly it is significantly higher in adult than in elderly but among adult population non type A pattern is more common and in elderly type A pattern is more common than non-type A pattern.

On comparison of type B pattern in adult and elderly it is significantly higher in adult than in elderly and also among adult population type B pattern is more common than non-type B pattern and in elderly non-type B pattern is more common than type B pattern. Again, on comparison of type C pattern in adult and elderly population no significant difference was

found. In both adult and elderly non type C pattern were more common.

## CONCLUSION

Knowledge of temporal bone pneumatization patterns and anatomy of medial wall of round window is very important during preoperative planning for otoneurological surgery particularly petrous apex cholesteatoma, cochlear implant surgery to avoid any wrong insertion to subcochlear canaliculus. Temporal bone pneumatization patterns also help during endoscopic infracochlear approach for vestibular schwannoma surgery or infracochlear schwannoma.

## REFERENCES

1. Cros O, Knutsson H, Andersson M et al (2016). Determination of the mastoid surface area and volume based on micro-CT scanning of human temporal bones. Geometrical parameters depend on scanning resolutions. *Hear Res.* 340:127–134.
2. Lee DH, Jun BC, Kim DG et al (2005). Volume variation of mastoid pneumatization in different age groups: a study by three-dimensional reconstruction based on computed tomography images. *SurgRadiolAnat.* 27:37–42
3. Lee DH, Kim MJ, Lee S et al (2015). Anatomical factors influencing pneumatization of the petrous apex. *Clin Exp Otorhinolaryngol.* 2015; 8: 339–344

4. Marchioni D, Gazzini L et al (2021). Subcochlear canaliculus patterns in the pediatric and adult population: radiological findings and surgical implications. *Surg Radiol Anatomy*
5. Zhao P, Ding H et al (2018). Growth pattern of temporal bone pneumatization: a computed tomography study with consecutive age groups. *surg and Radiol Anatomy*
6. Proctor B, Bollobas B, Niparko JK (1986). Anatomy of the round window niche. *Ann Otol Rhinol Laryngol* 95: 444–446
7. Marchioni D, Alicandri-Ciufelli M et al (2015). The round window region and contiguous areas: endoscopic anatomy and surgical implications. *Eur Arch Otorhinolaryngol*. 272:1103–1112
8. Marchioni D, Soloperto D et al (2016). Round window chamber and fustis: endoscopic anatomy and surgical implications. *SurgRadiolAnat*. 38:1013–1019
9. Nevoux J, Loundon N, Leboulanger N et al (2010). Cochlear implant in the carotid canal. Case report and literature review. *Int J PediatrOtorhinolaryngol*. 74: 701–703
10. Lang H, Nishimoto E, Xing Y, et al (2016). Contributions of mouse and human hematopoietic cells to remodeling of the adult auditory nerve after neuron loss. *Mol Ther*
11. Rask-Anderson H, Bostrom M, Gerdin B, et al (2005). Regeneration of human auditory nerve. In vitro/in vivo demonstration of neural progenitor cells in adult human and guinea pig spiral ganglion. *Hear Res*. 203(1–2): 180–91
12. Nayagam BA, Edge AS (2015). Stem cells for the replacement of auditory neurons. *Springer handbook of auditory research*.52: 263–86
13. Gao X, Zhao Y, Stemmer-Rachamimov AO, et al (2015). Anti-VEGF treatment improves neurological function and augments radiation response in NF2 schwannoma model. *Proc Natl Acad Sci U S A*. 112(47): 14676–81
14. Nithyashri J, Kulanthaivel G (2012). Fourth International Conference on Advanced Computing (ICoAC) - Classification of human age based on Neural Network using FG-NET Aging database and Wavelets. 1–5